

# The Beauty of Grey

## Radiographic technique and positioning in sea turtles

Nancy S. Mettee, D.V.M.; Melissa Ranly, Hospital Coordinator; Sandy Fournies, Rehabilitation Specialist

### Introduction

Accurate diagnosis of sea turtle disease requires the use of diagnostics. The minimum data-base is: physical exam (in and out of the water), a complete blood cell count (including white blood cell differential), chemistry panel, and full body radiographs. Many veterinary hospitals have x-ray machines and are willing to donate their use and assist with the taking of the films or digital images if approached. Once the images have been obtained, interpretation may be accomplished onsite by trained personnel or the images emailed to a veterinarian for evaluation.

**The benefits of radiographic imaging include:** it is a non invasive, high yield diagnostic; physical or chemical restraint is not typically required; low cost per plate (once equipment is acquired or if donated from a local DVM or MD). Radiographs are useful to evaluate: fractures, dislocations, GI obstructions, lung pathology, and foreign body ingestion; images can be photographed and emailed allowing diagnostic assistance.

**The drawbacks of radiographic imaging include:** interpretation can be challenging; equipment is not portable; cost of X-Ray machine and developer is prohibitive; use of equipment requires radiation certification and monitoring; use of the x-ray machine requires training; anatomical differences make for poor image contrast in the coelom (lack of coelomic fat, no distinct thorax/abdomen, loss of detail as image is take thru the carapace and plastron).

*Radiographs provide a two dimensional image of a three dimensional structure, thus several views are required to evaluate cranial-caudal and left-right. Careful positioning is crucial to accurate interpretation.*

*Radiographs provide information based on the variation of tissue density: gas or air will appear black, bone or metal (flipper and PIT tags) appears white, soft tissue or fluid appears grey.*

*\*Note that most plastics are radiolucent and will not appear on a radiograph.*

### Patient Preparation

Prior to taking radiographs turtles must be cleaned of barnacles as they will appear on the image and confound interpretation. Care should be taken to not damage the scutes or the bone beneath. Pressure at the base of the barnacle with a periosteal elevator, screwdriver, or chisel is sufficient to pry the barnacle loose. Sometimes a gentle tap with a hammer (on the instrument) may be needed to remove large individuals. Barnacles on soft tissue can often be removed by hand.

Anesthesia or sedation is not required.

### Standard Views

Radiographic views are named based on the movement of the beam thru the patient to the plate. Three standard views are used, a dorso-ventral (DV) view, an antero-posterior (AP) view, and a right (Lat) lateral view. Because sea turtles lack a diaphragm, the last two require **horizontal placement of the x-ray beam** to avoid ventral displacement of the lungs via the viscera. Make sure the patient is as near to the plate as possible to avoid magnification.

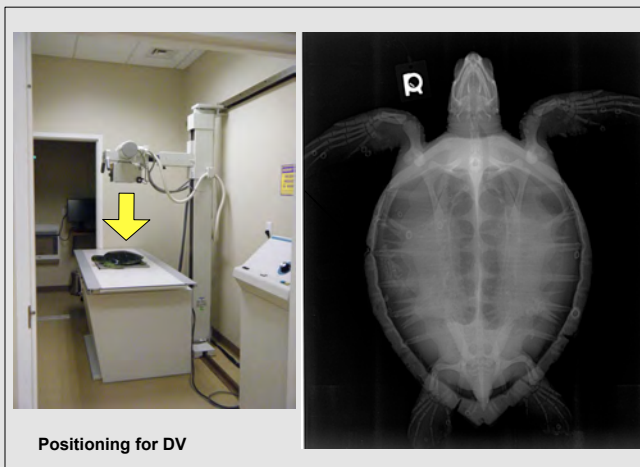
Focal film distance (from machine to plate) should remain a consistent 40-42 inches.

Technique will vary with size of the turtle, but is based on patient measurement. Measure from the highest point on the carapace for the DV. Technique can be determined with the help of experienced radiology technicians but standard abdominal technique is a good starting point for the DV and Lat. For the AP double the time of the exposure. Large turtles may require several plates to image completely.

### Diagnostic Use

The DV view allows visualization of the left and right sides of the turtle with the lungs superimposed over the viscera. The bones of the plastron and carapace, pelvic and pectoral girdles are clearly visible, along with the trachea and left and right lungs. Pathology in the gastrointestinal tract can include: shell impaction of the intestine, foreign body ingestion, and hook/line/sinker. This positioning is also good for diagnosis of bone infection, presence of eggs, and tissue necrosis. In large patients a separate skull DV is needed.


The AP and Lateral views are utilized primarily for viewing intestinal gas, lung pathology, and carapace structure.



Positioning for DV



Positioning for AP view



Positioning for Lateral view